

# Mural Attenuation in Normal Small Bowel and Active Inflammatory Crohn's Disease on CT Enterography: Location, Absolute Attenuation, Relative Attenuation, and the Effect of Wall Thickness

Mark E. Baker<sup>1</sup>  
 James Walter<sup>1</sup>  
 Nancy A. Obuchowski<sup>1,2</sup>  
 Jean-Paul Achkar<sup>3</sup>  
 David Einstein<sup>1</sup>  
 Joseph C. Veniero<sup>1</sup>  
 Jon Vogel<sup>3</sup>  
 Luca Stocchi<sup>3</sup>

**OBJECTIVE.** The purpose of our study was to measure relative and absolute wall attenuations and wall thickness in normal small bowel on contrast-enhanced CT enterography and to study the efficacy of relative attenuation, absolute attenuation, and wall thickness in distinguishing normal from active inflammatory Crohn's disease of the terminal ileum.

**MATERIALS AND METHODS.** Using a case-control study design, we reviewed 630 CT enterography examinations, of which 191 were normal and 36 had active inflammatory Crohn's disease in the terminal ileum. In healthy individuals, wall thickness and attenuation in distended and collapsed loops were measured in the duodenum and four abdominal quadrants. Wall thickness and attenuation were also measured in the terminal ileum. All measurements of intraarterial attenuation were taken at the same slice level. In the examinations of patients with Crohn's disease, only terminal ileum wall thickness and attenuation as well as arterial attenuation at the same slice level were measured. Normal segments were compared with a linear model. Terminal ileum data were fit to a multivariate logistic regression model.

**RESULTS.** Relative attenuation and absolute attenuation in the normal distended and collapsed duodenum and left upper quadrant were significantly greater than in all other segments ( $p < 0.001$  and  $< 0.048$  for relative attenuation and  $p < 0.001$  and  $< 0.032$  for absolute attenuation, respectively). Relative attenuation and wall thickness models and absolute attenuation and wall thickness models discriminated normal from active terminal ileum Crohn's disease significantly better than the same measurements without wall thickness ( $p = 0.017$  and  $0.001$ , respectively). When the bowel wall is  $> 3$  mm, a relative attenuation cutoff of 0.5 is 89% sensitive and 81% specific.

**CONCLUSION.** In normal small bowel, when wall measurement is taken into account, the duodenum and jejunum have a greater relative attenuation and absolute attenuation than other segments. Relative attenuation and absolute attenuation with wall thickness models discriminate normal from active terminal ileum Crohn's disease better than the same measurements without wall thickness.

**Keywords:** Crohn's disease, CT enterography, small bowel

DOI:10.2214/AJR.08.1267

Received May 19, 2008; accepted after revision August 18, 2008.

M. E. Baker is a speaker and consultant for E-Z-EM; he did not receive support for this investigation.

<sup>1</sup>Imaging Institute, Department of Quantitative Health Sciences and Digestive Disease Institute, Cleveland Clinic, 9500 Euclid Ave., Cleveland, OH 44195. Address correspondence to M. E. Baker (bakerm@ccf.org).

<sup>2</sup>Department of Quantitative Health Sciences, Cleveland Clinic, Cleveland, OH.

<sup>3</sup>Digestive Disease Institute, Cleveland Clinic, Cleveland, OH.

AJR 2009; 192:417-423

0361-803X/09/1922-417

© American Roentgen Ray Society

**A**t our institution, CT enterography is the radiographic method of choice in evaluating patients with Crohn's disease [1], virtually replacing both dedicated small-bowel series and small-bowel enteroclysis. To date, one group has investigated the differences between bowel wall attenuation of normal and active inflammatory Crohn's disease and the effect of bowel distention on attenuation [2, 3]. However, the precise relationship between measured bowel wall thickness and attenuation in healthy patients and those with Crohn's disease has not been fully evaluated. In addition, the only internal control used for comparison with an abnormal terminal ile-

um was the more proximal normal ileum, based on endoscopic findings. For comparison with follow-up studies, we used a more standardized method of assessing bowel wall attenuation vis-à-vis variation in contrast injection. Also, an internal control that is more rigorous than presumably normal small bowel should be developed.

The objective of this study was to measure relative and absolute wall attenuations and wall thickness in normal small bowel on contrast-enhanced CT enterography and to determine the efficacy of relative attenuation, absolute attenuation, and wall thickness in distinguishing normal from active inflammatory Crohn's disease of the terminal ileum.

## Materials and Methods

All CT enterography examinations performed at our institution are entered into an institutional review board–approved, HIPAA-compliant database. Written informed consent was waived for this study. This database includes the medical record number, date of CT enterography, and indication for scanning. In addition, a separate institutional review board–, HIPAA-compliant chart review was approved to record endoscopic, pathologic, and clinical findings as well as outcome for patients in this study.

### Patient Population

For this study, we used a case-control study design. Over a 12-month period (June 7, 2005–May 30, 2006), 630 CT enterography examinations using low–Hounsfield unit oral contrast material were performed at our institution. Four hundred three examinations were excluded because of known or suspected Crohn's disease without endoscopically or biopsy-confirmed active inflammation of the terminal ileum within 2 months of CT enterography ( $n = 300$ ), probably normal but insufficient clinical confirmation based on follow-up and the referring clinician's assessment ( $n = 41$ ), ulcerative or indeterminate colitis ( $n = 37$ ), celiac disease ( $n = 5$ ), repeat evaluations ( $n = 5$ ), history of abdominal or pelvic radiation ( $n = 4$ ), metastatic disease to the mesentery ( $n = 4$ ), scans performed without IV contrast media ( $n = 3$ ), incorrect medical record number entered in database ( $n = 2$ ), protein-losing enteropathy ( $n = 1$ ), and inappropriately administered high-attenuation oral contrast media ( $n = 1$ ).

### Normal or Control Population

Of the remaining 227 examinations, 191 were performed in definitely healthy ( $n = 77$ ) or probably healthy patients ( $n = 114$ ), of whom 131 were female and 60 male with a mean age of 46.6 years (range, 16–85 years). The definitely healthy patients were confirmed on ileocolonoscopy ( $n = 55$ ), capsule endoscopy ( $n = 10$ ), colonoscopy and capsule endoscopy ( $n = 4$ ), and surgery performed after CT enterography ( $n = 8$ ). The probably healthy patients were confirmed on the basis of clinical findings by a board-certified gastroenterologist or colorectal surgeon. Most of these patients ( $n = 61$ ) had abdominal pain and were diagnosed with irritable bowel syndrome.

### Active Inflammatory Crohn's Disease Population

Of the remaining 227 examinations, 36 were performed in patients with active inflammatory Crohn's disease involving the terminal ileum. The patients were 23 females and 13 males with a

mean age of 40 years (range, 17–70 years). The time of Crohn's disease diagnosis was documented in the electronic medical record in only 27 of the 36 patients. The mean duration of disease in these patients was 13 years (range, 1–39 years). At the time of the CT enterography, 32 of the 36 patients were being treated with a variety of medications for Crohn's disease, including mesalamine, prednisone, budesonide, azathioprine, 6-mercaptopurine, adalimumab, and infliximab. Only one patient already treated with mesalamine and azathioprine was given prednisone between the confirmatory ileocolonoscopy and CT enterography performed 3 weeks later. Furthermore, all patients receiving medication had been taking that medication for at least 2 months before both examinations. The patients with active inflammatory Crohn's disease were subclassified into definitely active and probably active using the criteria established by Bodily et al. [2]. Those authors stated:

...the presence of Crohn disease was considered probably active if (a) ileoscopy revealed stenosis, ulcerations, granularity or friability (but not erythema or mucosal edema alone) combined with normal or no biopsy findings, (b) ileoscopic results were normal but acute or chronic ileitis was observed at biopsy, or (c) ileoscopy showed erythema, granularity, friability or edema and biopsy revealed acute ileitis. The presence of Crohn disease was considered definitely active if ileoscopy revealed erosions and/or ulcerations or stenosis or if abnormal ileoscopic results were combined with the finding of chronic ileitis at biopsy.

Classifying patients into definite and probable Crohn's disease was done by one of the authors, a board-certified gastroenterologist with 10 years of dedicated experience treating patients with inflammatory bowel disease. He retrospectively assessed the endoscopic findings without knowledge of the CT enterography findings. Of the 36 patients with Crohn's disease, 32 had definite disease and four had probable disease.

All colonoscopy examinations and surgery were performed within 60 days of CT enterography (mean, 12.3 days; median, 5 days; range, 1–60 days); 17 of 36 were performed within 3 days of each other, and 21 of 36 within 10 days of each other.

### CT Enterography Protocol

All CT enterography examinations in our institution are performed on MDCT scanners (Sensation-16 or Sensation-64, Siemens Medical Solu-

tions). With the 16-MDCT unit, scanning is performed using 0.75-mm collimation, reconstructing with 1-mm axial slices every 0.8 mm, and obtaining 3-mm contiguous axial slices. With the 64-MDCT unit, scanning is performed using 0.6-mm collimation, reconstructing with 1-mm axial slices every 0.8 mm, and obtaining 3-mm contiguous axial slices. Although we reconstructed 2-mm coronal maximum-intensity-projection images from the 1-mm slices for clinical interpretation, we measured the bowel wall attenuation and thickness only on the 3-mm axial scans for this investigation.

Before scanning, the patient ingests a total of 1,350 mL of a neutral contrast agent (VoLumen [0.1% barium suspension], E-Z-EM) over a 60-minute period. After 40 minutes, a nurse establishes IV access. After ingesting the oral contrast agent, the patient is placed on the scanner. Every attempt is made to begin scanning 60 minutes after the start of ingestion. If the patient is unable to ingest the oral agent, a feeding or nasogastric tube is placed in the stomach. We do not know how many patients in this study required placement of a tube; but, anecdotally, this is a rare occurrence. In our study, 482 patients were scanned using this protocol. Since March 2006, a modification to the oral contrast agent ingestion protocol was instituted in an attempt to improve jejunal distention. The volume and timing of the neutral contrast agent ingestion remain the same. However, at 60 minutes, the patient is given an additional 225 mL of water to ingest over 5–10 minutes. The patient is then placed on the scanner and the examination started. Every attempt is made to begin scanning 70 minutes after the start of oral contrast ingestion. In this study, 148 examinations were scanned using this new protocol. In our subsequent analysis, we did not compare the results from the two population subsets.

IV contrast enhancement was achieved with Ultravist-300 (iopromide, Bayer HealthCare), 150 mL, injected at 3 mL/s. Scanning began 70 seconds after the start of the contrast injection and was performed using a single breath-hold, with scanning duration of 18–22 seconds.

### Bowel Wall Attenuation and Thickness Measurements

On the 3-mm axial images of the healthy patients, we retrospectively measured wall thickness and wall attenuation for the duodenum, right upper quadrant (RUQ), left upper quadrant (LUQ), right lower quadrant (RLQ), left lower quadrant (LLQ) (collapsed and dilated) as well as the terminal ileum. At the same table position where the wall thickness and attenuation were measured, arterial attenuation was also measured, either in the aorta or in the iliac arteries, depending on the

## CT Enterography of Small Bowel in Crohn's Disease

level of the scan. In patients with active inflammatory Crohn's disease, only the wall thickness, attenuation of the terminal ileum, and arterial attenuation at the same slice level were measured. We did not measure the other segments as in the healthy population because we had no confirmation that these segments were normal.

The measurements were made on a workstation (Wizard, Siemens Medical Solutions). All bowel wall attenuation measurements were made using a round 25-pixel region of interest (ROI) placed over the bowel wall. This is the smallest ROI available on the workstation and is only round on this device. The bowel wall attenuation was determined by slowly moving the ROI around the circumference of the wall, keeping the ROI over the wall. The highest attenuation measured was the absolute attenuation used for the analysis. When mural stratification—an increase in inner wall attenuation—was present, the highest attenuation of the inner wall was measured. The intraarterial—aorta, common iliac artery, or external iliac artery—attenuation also was made using the same 25-pixel ROI placed over the center of the vessel. We chose the center of the vessel to measure the maximum intraarterial attenuation, minimizing partial volume effect and laminar flow. The relative attenuation was calculated by absolute attenuation divided by arterial attenuation.

To determine wall thickness, we first measured the inner and outer diameters of the bowel lumen in the loop most distended in each abdominal quadrant. To obtain the wall thickness, the inner diameter was subtracted from the outer diameter and divided by 2. The most collapsed loop in each quadrant was also measured. In most cases, this loop was completely collapsed so that no inner diameter could be measured. In these cases, the entire bowel wall diameter was measured and divided by 2 to obtain the wall thickness. In cases in which there were no distended loops, only the collapsed loop was measured.

We measured bowel loops in the RUQ, LUQ, RLQ, and LLQ of the abdomen. We used this method in an attempt to measure the normal bowel from the proximal jejunum (LUQ) to the distal ileum (RLQ), assuming that the other quadrants would most likely represent intervening bowel, with the RUQ usually representing the distal jejunum or proximal ileum and the LLQ usually representing the proximal ileum. Two perpendicular planes, one passing parallel to the midline of the spine and the other parallel to the iliac crests, defined the four quadrants. We used these landmarks because they are consistent. The duodenum was measured at its points of maximum distention and collapse, generally identified in the regions of its second and third portions, respectively. Last, the terminal ileum was measured

within 3 cm of the ileocecal valve. Only one measurement of the terminal ileum—the mural attenuation and wall thickness—was made, regardless of whether the segment was distended or collapsed. Thus, each patient had 11 measurements for bowel wall attenuation and thickness.

All measurements were performed by one of the authors without knowledge of the clinical findings and were reviewed by another author, also without knowledge of the clinical findings. This review was intended to determine whether the ROI placement on the bowel wall and the wall measurements were correct. If not, they were adjusted. We did not document how often an adjustment was made. The reviewing author has 23 years of experience as an abdominal radiologist and had interpreted more than 300 CT enterography examinations at the time of this investigation.

### Statistical Analysis

To determine whether the data from “probably normal” and “definitely normal” patients could be pooled, two-sample Student's *t* tests were used to compare probably normal and definitely normal patients' attenuation and wall thickness values in each segment for both collapsed and distended segments. A total of 30 comparisons were made using a significance level of 0.05. Using the hypothesis that the two normal groups are from the same population, we expect 1.5 comparisons to reach statistical significance by chance alone. Of the 10 relative attenuation values, probably normal and definitely normal patients differed

significantly only in collapsed loops in the LLQ (probably normal mean = 0.54 [SD = 0.08] vs definite normal mean = 0.57 [SD = 0.07]; *p* = 0.023). Probably normal and definitely normal patients did not differ significantly on any of the 10 absolute attenuation values. Of the 10 wall thickness values, probably normal and definitely normal patients differed significantly only in distended loops in the RLQ (probably normal mean = 0.23 cm [SD = 0.07 cm] vs definitely normal mean = 0.22 cm [SD = 0.05 cm]; *p* = 0.042). These results were with the hypothesis that these two normal groups were from the same population. Thus, for the remaining analyses, we pooled the results of definitely and probably normal patients into one normal sample.

To compare segments in normal patients, we fit a generalized linear model to the data, treating the attenuation value as the dependent variable and the segment (i.e., duodenum, LLQ, RLQ, LUQ, and RUQ) and measured wall thickness as the independent variables. If a significant difference between segments was found at the 0.05 level, then the segments were compared using the Student-Newman-Keuls test for multiple comparisons. The methods used to assess multiple segments from the same patient took into account that the segments were from the same patient by treating patient as a factor in the models (thus taking into account the potential correlation between segments from the same patient).

We fit a multivariate logistic regression model to the terminal ileum data. Because there were so

**TABLE 1: Mean Relative Attenuation, Absolute Attenuation, and Wall Thickness of Collapsed and Distended Segments of Normal Bowel**

Bowel Segment	Mean Relative Attenuation	Mean Absolute Attenuation (HU)	Wall Thickness (cm)
Duodenum			
Collapsed	0.59 (0.09)	108.30 (19.40)	0.50 (0.19)
Distended	0.50 (0.09)	91.20 (16.68)	0.33 (0.15)
Left upper quadrant			
Collapsed	0.58 (0.08)	106.09 (16.04)	0.69 (0.17)
Distended	0.44 (0.09)	82.21 (16.31)	0.28 (0.11)
Right upper quadrant			
Collapsed	0.52 (0.09)	95.90 (17.75)	0.54 (0.18)
Distended	0.41 (0.07)	75.89 (15.36)	0.24 (0.08)
Left lower quadrant			
Collapsed	0.55 (0.07)	97.72 (15.72)	0.57 (0.15)
Distended	0.44 (0.07)	77.34 (13.46)	0.25 (0.07)
Right lower quadrant			
Collapsed	0.54 (0.08)	94.62 (16)	0.52 (0.14)
Distended	0.42 (0.07)	73.51 (12.62)	0.23 (0.06)

Note—Numbers in parentheses are SDs.

few probably active inflammatory Crohn's disease patients (4/36), these were grouped with the definitely active inflammatory Crohn's disease patients. The dependent variable was disease status (normal or Crohn's disease with active inflammation); the independent variables were wall thickness, wall attenuation, and their interaction. We fit separate models for absolute attenuation and relative attenuation. Nested models were compared using the likelihood ratio test. For both absolute attenuation and relative attenuation, we found the best parsimonious model (i.e., a parsimonious model is one that performs well and has as few parameters as possible); we then compared the areas under the receiver operating characteristic (ROC) curves of these two models to determine which model is better at distinguishing normal from Crohn's disease. A significance level of 0.05 was used.

**Results**

*Summary of Normal Segments*

Overall, overlap occurred in mean relative and absolute attenuations and wall thickness of the normal segments, regardless of whether the segment was distended or collapsed (Table 1). However, taking into account the measured wall thickness, significant differences were seen in relative attenuation and absolute attenuation between the segments for both distended and collapsed loops ( $p < 0.001$ ) (Table 2).

*Relative Attenuation of Normal Distended Segments*

For distended loops, taking into account the measured wall thickness, significant dif-

ferences were seen in relative attenuation between the segments ( $p < 0.001$ ) (Table 2). The duodenum had a significantly greater relative attenuation than all other segments ( $p < 0.001$ ). Furthermore, attenuations of the LUQ and LLQ were significantly greater than those of the RUQ and RLQ ( $p < 0.048$ ).

*Relative Attenuation of Normal Collapsed Segments*

For collapsed loops, taking into account the measured wall thickness, significant differences were seen in relative attenuation between the segments ( $p < 0.001$ ) (Table 2). Attenuations of the duodenum and LUQ were significantly greater than those of all other segments ( $p < 0.048$ ).

*Absolute Attenuation of Normal Distended Segments*

For distended loops, taking into account the measured wall thickness, significant differences were seen in absolute attenuation between the segments ( $p < 0.001$ ) (Table 2). Attenuation of the duodenum was significantly greater than that of all other segments ( $p < 0.001$ ). Attenuation of the LUQ was significantly greater than that of the RUQ, LLQ, and RLQ ( $p < 0.002$ ), and attenuation of the LLQ was greater than that of the RLQ ( $p = 0.001$ ).

*Absolute Attenuation of Normal Collapsed Segments*

For collapsed loops, taking into account the measured wall thickness, significant differences were seen in absolute attenuation

between the segments ( $p < 0.001$ ) (Table 2). Attenuations of the duodenum and LUQ were significantly greater than those of the LLQ, RUQ, and RLQ ( $p < 0.032$ ).

*Comparison of Normal Terminal Ileum and Terminal Ileum with Crohn's Disease and Active Inflammation*

Some overlap occurred between mean relative and absolute attenuations and wall thickness of the normal terminal ileum and the terminal ileum with Crohn's disease (Table 3, Figs. 1 and 2).

The logistic regression model using relative attenuation and wall thickness to distinguish normal from Crohn's disease patients with inflammation had a c-index (area under the ROC curve) of 0.895 (SE = 0.032) (Fig. 3) and was significantly better than a model without wall thickness ( $p = 0.017$ ); the interaction term was not significant. Similarly, the logistic regression model using absolute attenuation and wall thickness to distinguish normal from Crohn's disease patients with inflammation (c-index = 0.913, SE = 0.025) had a significantly better fit than a model without wall thickness ( $p = 0.001$ ); the interaction term was not significant. Comparing the model with relative attenuation and wall thickness to the model of absolute attenuation and wall thickness, the difference is not statistically significant ( $p = 0.267$ ) (Fig. 3).

A simple decision rule for distinguishing Crohn's disease from normal ileum is to have cutoff points for wall thickness and attenuation values (Table 4). For relative attenuation, a cutoff of 0.5 yields a sensitivity of 89% and specificity of 74% (Table 4). If wall thickness exceeds 0.3 cm, then the sensitivity remains the same (89%) but the specificity improves to 81%.

**Discussion**

CT enterography is increasingly replacing other methods, including capsule endoscopy, of small-bowel assessment in patients with Crohn's disease[1-8]. Several recent investigations have shown that CT enterography is efficacious in detecting Crohn's disease with active inflammation as well as identifying its complications, including stricture and fistulas formation [1-3]. Bodily et al. [2] found that quantitative measures of absolute wall attenuation and wall thickness of the terminal ileum correlated significantly with active inflammatory Crohn's disease. However, to achieve a higher sensitivity, those authors speculated that the use of the absolute atten-

**TABLE 2: Comparison of Relative Attenuation and Absolute Attenuation in Distended and Collapsed Normal Segments of Small Bowel When Taking into Account Measured Bowel Wall Thickness**

Bowel Segment	Overall Comparison of Bowel Segments <sup>a</sup>	Specific Comparisons of Bowel Segments <sup>b</sup>	<i>p</i>
Distended			
Relative attenuation	<0.001	D > LUQ, LLQ, RLQ, and RUQ LUQ and LLQ > RLQ and RUQ	<0.001 ≤0.048
Absolute attenuation	<0.001	D > LUQ, LLQ, RUQ, and RLQ LUQ > LLQ, RUQ, and RLQ LLQ > RLQ	<0.001 ≤0.002 0.001
Collapsed			
Relative attenuation	<0.001	D and LUQ > LLQ, RUQ, and RLQ	≤0.048
Absolute attenuation	<0.001	D and LUQ > LLQ, RUQ, and RLQ	≤0.032

Note—D = duodenum, LUQ = left upper quadrant, RUQ = right upper quadrant, LLQ = left lower quadrant, RLQ = right lower quadrant.

<sup>a</sup>*p* values for null hypothesis of no difference between any segments.

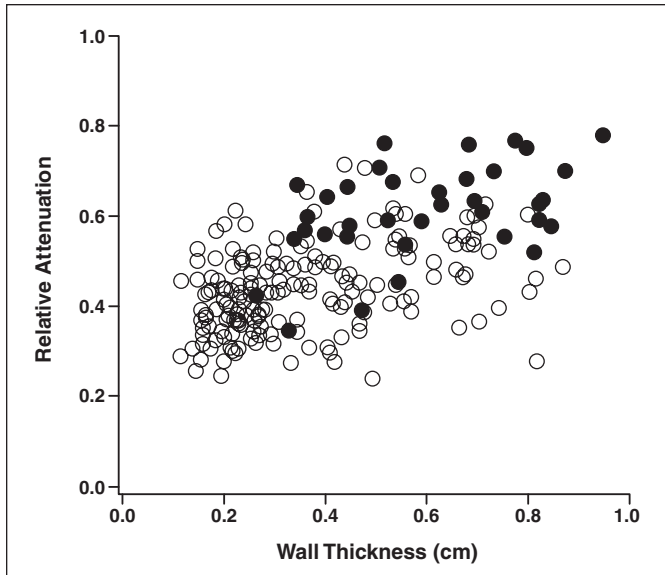
<sup>b</sup>*p* values for pairwise comparisons between segments.

## CT Enterography of Small Bowel in Crohn's Disease

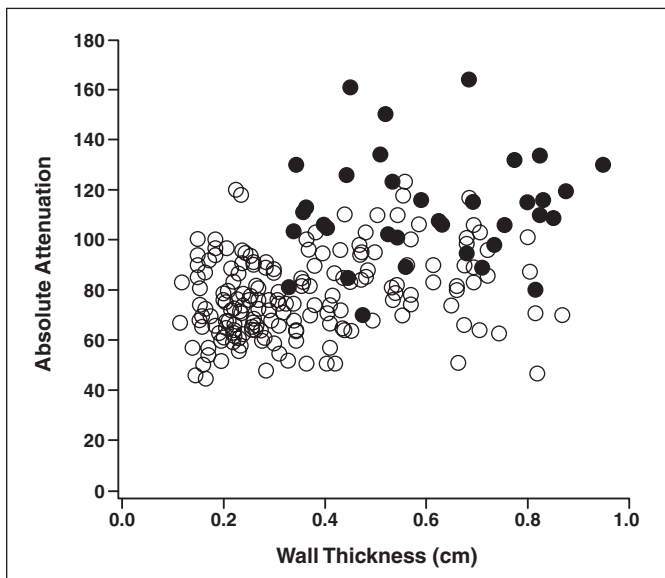
**TABLE 3: Mean Relative Attenuation, Absolute Attenuation, and Wall Thickness of Normal Terminal Ileum and Terminal Ileum in Crohn's Disease**

Terminal Ileum	Mean Relative Attenuation	Mean Absolute Attenuation (HU)	Wall Thickness (cm)
Normal	0.44 (0.09)	77.60 (16.20)	0.36 (0.19)
Crohn's disease	0.61 (0.10)	111.44 (21.80)	0.60 (0.19)

Note—Numbers in parentheses are SDs.



**Fig. 1**—Scatterplot of normal and abnormal terminal ileum shows relative attenuation vis-à-vis wall thickness. Open circles indicate normal terminal ileum; black dots indicate Crohn's disease.



**Fig. 2**—Scatterplot of normal and abnormal terminal ileum shows absolute attenuation vis-à-vis wall thickness. Open circles indicate normal terminal ileum; black dots indicate Crohn's disease.

uation model of the terminal ileum might be preferable. Using absolute bowel wall attenuation is appropriate for an individual patient on one examination. But comparing absolute attenuation of the bowel wall with a subsequent examination without a control may not

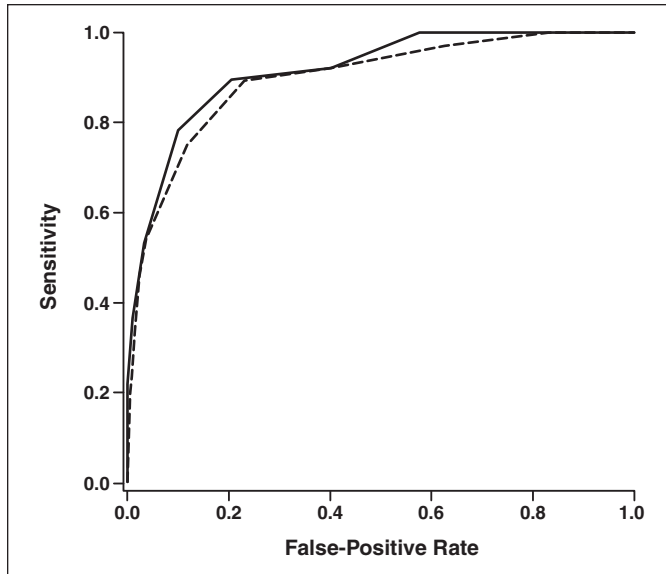
be appropriate because the level of vascular attenuation on a subsequent examination could be different. Thus, a potentially more consistent means of normalizing bowel attenuation is necessary. Normalizing bowel wall attenuation with arterial attenuation at

the same level could potentially allow comparisons between examinations performed at different times.

In another article, Booya et al. [3] evaluated the effect of bowel distention and small-bowel location (jejunal vs ileal) on overall attenuation. Until this investigation, it was thought that bowel wall attenuation after contrast injection was equal regardless of the segment evaluated [9]. Using absolute attenuation once again, Booya et al. found that distended jejunal loops had a significantly greater attenuation than distended ileal loops. In addition, the attenuation of collapsed loops was greater than that of distended loops.

We have confirmed and expanded on the work of Booya et al. [3]. Both the relative attenuation and the absolute attenuation of the distended duodenum are greater than those of all other segments, including the proximal jejunum; and the relative attenuation and absolute attenuation of the distended proximal jejunum are greater than that of the distal ileum. The relative and absolute attenuations of the collapsed duodenum and proximal jejunum are greater than those of the remainder of the bowel, including the distal ileum. This information is important when attempting to determine whether a proximal bowel segment is normal or abnormal on the basis of a quantitative measure. Because the proximal small bowel has a greater relative attenuation and absolute attenuation than the distal small bowel, it is likely that there will be considerable overlap between normal and active inflammatory Crohn's disease if values for normal and abnormal terminal ileum are used to make this distinction (Tables 1 and 3).

In our study, we could also distinguish normal from active inflammatory Crohn's disease affecting the terminal ileum. Unlike Bodily et al. [2], we found that wall thickness was an important variable in distinguishing normal from inflammatory Crohn's disease in our population. In addition, we found that the relative attenuation bowel wall thickness model was not significantly different from the absolute attenuation bowel wall thickness model. Because of the advantages of relative attenuation in the same patient on subsequent scans as well as among all patients, we believe that relative attenuation should become the quantitative means of assessing the presence or absence of active inflammatory Crohn's disease of the terminal ileum. When the bowel wall is > 3 mm, using a cutoff of 0.5, we achieved a sensitivity of 89% and a specificity of 81% (Table 4).



**Fig. 3**—Receiver operating characteristic (ROC) curves for performance of relative attenuation and wall thickness model (dashed line) and absolute attenuation and wall thickness model (solid line). The c-index (area under ROC curve) of relative attenuation and wall thickness model was 0.895 (SE = 0.032); c-index of absolute attenuation and wall thickness model was 0.913 (SE = 0.025). Difference was not statistically different ( $p = 0.267$ ).

**TABLE 4: Cutoff Points for Relative Attenuation in Distinguishing Crohn's Disease Involving the Terminal Ileum from Normal Ileum**

Relative Attenuation Cutoff	Sensitivity (%)	Specificity (%)
0.5	89	74
0.5 <sup>a</sup>	89	81

<sup>a</sup>If wall thickness is > 3 mm.

An advantage of our study is that we used a method of assessing bowel wall thickness and attenuation that can be used in difficult cases on any workstation. Booya et al. [3] and Bodily et al. [2] used a method of measuring bowel wall attenuation and thickness that is not readily available in clinical practice. Although they measured the maximum pixel across the bowel wall, and we measured the mean attenuation, our results are similar to their two investigations. We therefore believe that this simpler method is valid and can distinguish normal bowel wall from inflammatory Crohn's disease as accurately as the more sophisticated software.

One limitation of our study is that the attenuation of the bowel wall after contrast enhancement varies depending on the volume and rate of delivery of contrast media, the timing of the scan vis-à-vis the start of contrast media injection, the size of the patient, and the IV catheter site. This is a problem with both absolute and relative attenuation measurements. However, we believe that relative attenuation is a better measure than absolute attenuation because it provides a more consistent means of internally controlling changes in overall contrast delivery. If an institution uses a consistent scanning time

after the start of contrast media injection, the relative attenuation of the bowel wall should be a more consistent method of assessing any change on follow-up examinations performed in the same patient.

Another potential limitation is that we do not know the attenuation of the bowel wall before the administration of contrast media, measuring the attenuation of bowel wall only after contrast media injection. Thus, we do not know how much the contrast-enhanced attenuation was due to a more or less attenuating bowel wall before contrast enhancement. Unenhanced scans of the entire abdomen and pelvis add to the radiation dose of the patient and thus are not routinely performed. Regardless, we as well as others [2, 3] have shown that bowel wall attenuation alone can distinguish normal from active inflammatory Crohn's disease with a high degree of sensitivity and specificity.

We also did not include a large number ( $n = 300$ ) of patients with known Crohn's disease because they had not had recent (within 2 months) confirmation of active inflammation of the terminal ileum. We do not know whether these patients had milder disease and if so, whether any bias exists in our study as a result. However, we thought that we

should apply strict criteria of active inflammation to the disease cohort rather than rely on clinical impressions. Conversely, because our study used a case-control design, we were able to include a larger number of healthy patients than have been previously reported.

Another potential limitation of our study is that scanning started at approximately 70 seconds after the start of the injection of contrast media. A recent study has shown that the mean time to peak enhancement of the normal small-bowel wall is 49 seconds [10]. The authors of that study did not take into account the location of the small bowel measured, assuming that the small-bowel wall enhances uniformly, proximal to distal, as reported by Horton et al. [9]. The results in Booya et al. [3] and our results suggest that this may not be the case. Furthermore, the patients studied by Bodily et al. [2] were scanned 70 seconds after the start of the injection of contrast media. In addition, in a recent MR study, Florie et al. [11] showed that the maximum enhancement of small bowel in active Crohn's disease can occur at an average of 66 seconds after the start of contrast media injection and may vary between 27 and 105 seconds. Furthermore, the investigation of Vandenbroucke et al. [12] suggests that active inflammatory Crohn's disease can be distinguished from normal ileum regardless of scanning during the enteric phase (40 seconds after contrast injection) or the hepatic phase (70 seconds after contrast injection).

One other concern in our findings is that in clinical practice, quantitative means to measure bowel wall attenuation will not be used or are not necessary. In our practice, as in most practices, we generally rely on visual identification of increased wall attenuation and wall thickening, as well as other findings of inflammation such as perivascular engorgement, to diagnose Crohn's disease. However, sometimes the visual findings are subtle or equivocal. In these instances, we believe that quantitative means are helpful in distinguishing normal from abnormal. Further, Bodily et al. [2] found that quantitative measures are more sensitive than visual inspection in the detection of Crohn's disease.

In conclusion, when wall measurement is taken into account, the normal duodenum and jejunum have greater relative attenuation and absolute attenuation than other segments of the bowel. Regardless of the attenuation measurement, wall thickness is an important covariable. Taking into account wall thickness, relative attenuation appears

## CT Enterography of Small Bowel in Crohn's Disease

to be the equivalent of absolute enhancement in distinguishing normal bowel from active inflammatory Crohn's disease of the terminal ileum and thus may be more appropriate for follow-up comparisons. If the bowel wall is > 3 mm, a relative attenuation cut-off of 0.5 can reliably distinguish normal terminal ileum from active inflammatory Crohn's disease.

### References

1. Vogel J, Moreira A, Baker M, et al. CT enterography for Crohn's disease: accurate preoperative diagnostic imaging. *Dis Colon Rectum* 2007; 50: 1761–1769
2. Bodily KD, Fletcher JG, Solem CA, et al. Crohn disease: mural attenuation and thickness at contrast-enhanced CT enterography—correlation with endoscopic and histologic findings of inflammation. *Radiology* 2006; 238:505–516
3. Booya F, Fletcher JG, Huprich JE, et al. Active Crohn disease: CT findings and interobserver agreement for enteric phase CT enterography. *Radiology* 2006; 241:787–795
4. Reittner P, Goritschnig T, Petritsch W, et al. Multiplanar spiral CT enterography in patients with Crohn's disease using a negative oral contrast material: initial results of a noninvasive imaging approach. *Eur Radiol* 2002; 12:2253–2257
5. Wold PB, Fletcher JG, Johnson CD, et al. Assessment of small bowel Crohn disease: noninvasive peroral CT enterography compared with other imaging methods and endoscopy—feasibility study. *Radiology* 2003; 229:275–281
6. Hara AK, Leighton JA, Sharma VK, et al. Imaging of small bowel disease: comparison of capsule endoscopy, standard endoscopy, barium examination, and CT. *RadioGraphics* 2005; 25:697–718
7. Hara AK, Leighton JA, Heigh RI, et al. Crohn disease of the small bowel: preliminary comparison among CT enterography, capsule endoscopy, small-bowel follow-through, and ileoscopy. *Radiology* 2006; 238:128–134
8. Paulsen SR, Huprich JE, Fletcher JG, et al. CT enterography as a diagnostic tool in evaluation small bowel disorders: review of clinical experience with over 700 cases. *RadioGraphics* 2006; 26:641–662
9. Horton KM, Eng J, Fishman EK. Normal enhancement of the small bowel: evaluation with spiral CT. *J Comput Assist Tomogr* 2000; 24:67–71
10. Schindera ST, Nelson RC, DeLong DM, et al. Multi-detector row CT of the small bowel: peak enhancement temporal window—initial experience. *Radiology* 2007; 243:438–444
11. Florie J, Wasser MNJM, Arts-Cieslik K, Akkerman EM, Siersema PD, Stoker J. Dynamic contrast-enhanced MRI of the bowel wall for assessment of disease activity in Crohn's disease. *AJR* 2006; 186:1384–1392
12. Vandenbroucke F, Mortelé KJ, Tatli S, et al. Non-invasive multidetector computed tomography enterography in patients with small bowel Crohn's disease: is a 40-second delay better than 70 seconds? *Acta Radiol* 2007; 48:1052–1060